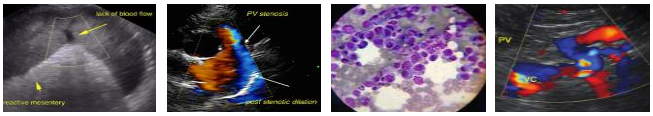

SonoPath.com
1-800-838-4268 info@sonopath.com

DATE

3/1/23

PERFORMED BY:

Sarah Pender, CVT

INTERPRETED BY

Keith Blass, DVM, MS, DACVIM (Cardiology)

PATIENT

Gizmo Wood

SPECIES

Canine

BREED

Pomeranian

SEX

FS

AGE

10 y

WEIGHT

6 lb

HOSPITAL NAME

SVS Imaging QC

REFERRING VET

Dr. Joy

PRESENTING CLINICAL SIGNS

History: Coughing. Radiographs show an enlarged cardiac silhouette. Started on furosemide, pimobendan, and benazepril on 2/27/22.

ECHOCARDIOGRAPHIC FINDINGS

2D, M-mode, and Doppler study.

There is mild left atrial dilation. The mitral valve leaflets are thickened and exhibit systolic prolapse. A mild to moderate jet of eccentric mitral regurgitation is present. There is mild left ventricular dilation. Left ventricular systolic function is hyperdynamic. The aorta and aortic valve are normal. Right atrial and right ventricular dimensions are normal. The tricuspid valve appears normal, though trace tricuspid regurgitation is present. The pulmonary artery and pulmonic valve are normal. No shunting lesions are visualized. No pericardial effusion or cardiac masses are seen.

LA – 19.9 mm
LVIDd – 20.5 mm
LVIDs – 10.2 mm
FS – 50%
LVOT – 1.75 m/s
RVOT – 1.85 m/s

ASSESSMENT/RECOMMENDATIONS

Degenerative mitral valve disease

This examination demonstrates mild to moderate regurgitation of blood across Gizmo's mitral valve resulting from degenerative valve disease. Secondary to her regurgitation, Gizmo has mild dilation of both her left atrium and left ventricle, though her left ventricular systolic function is well-preserved. As only mild left heart chamber dilation is present, it's unlikely that mainstem bronchial compression by Gizmo's left atrium is the cause of her cough. Gizmo's mitral valve disease is compensated, however, she could become at risk for the development of exercise intolerance, syncope, and labored breathing if her disease progresses, therefore, careful monitoring for these signs is recommended.

Continued use of pimobendan (1.25 mg am, 0.625 mg pm) is warranted based on this exam. As for furosemide and benazepril, the medications may be continued if they have improved Gizmo's cough, though no clear indication for their use is seen in her echocardiogram.

A recheck echocardiogram is recommended in 9 months. Repeat radiographs are recommended if Gizmo experiences difficulty breathing.

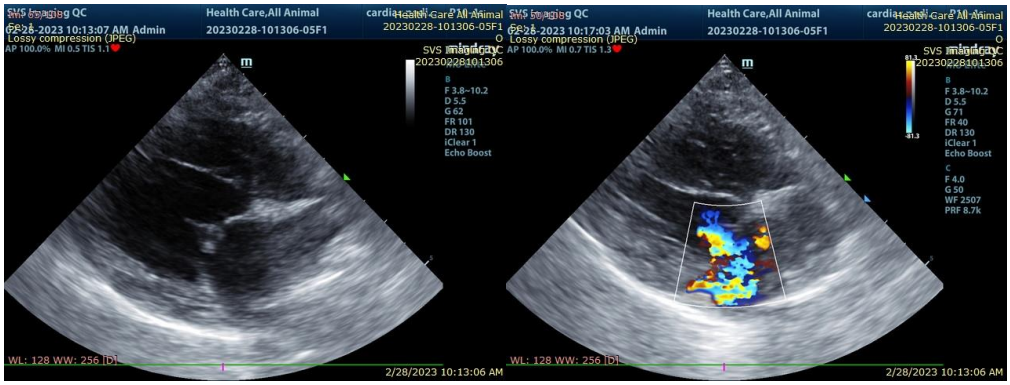

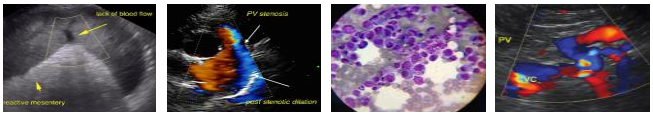

SonoPath.com
1-800-838-4268 info@sonopath.com

DATE

3/1/23

PERFORMED BY:

Sarah Pender, CVT

INTERPRETED BY

Keith Blass, DVM, MS, DACVIM (Cardiology)

PATIENT

Gizmo Wood

SPECIES

Canine

BREED

Pomeranian

SEX

FS

AGE

10 y

WEIGHT

6 lb

HOSPITAL NAME

SVS Imaging QC

REFERRING VET

Dr. Joy

The information and recommendations provided are based on the images presented by the referring veterinarian. No evaluation can be communicated regarding pathology that was not visible in the image/video clips provided.

Thank you for this referral. If the clinical or image interpretation does not parallel your findings or if I can be of any further assistance please contact me.

Keith Blass, DVM, MS, DACVIM (Cardiology)
KeithBlass@gmail.com
631-804-5754